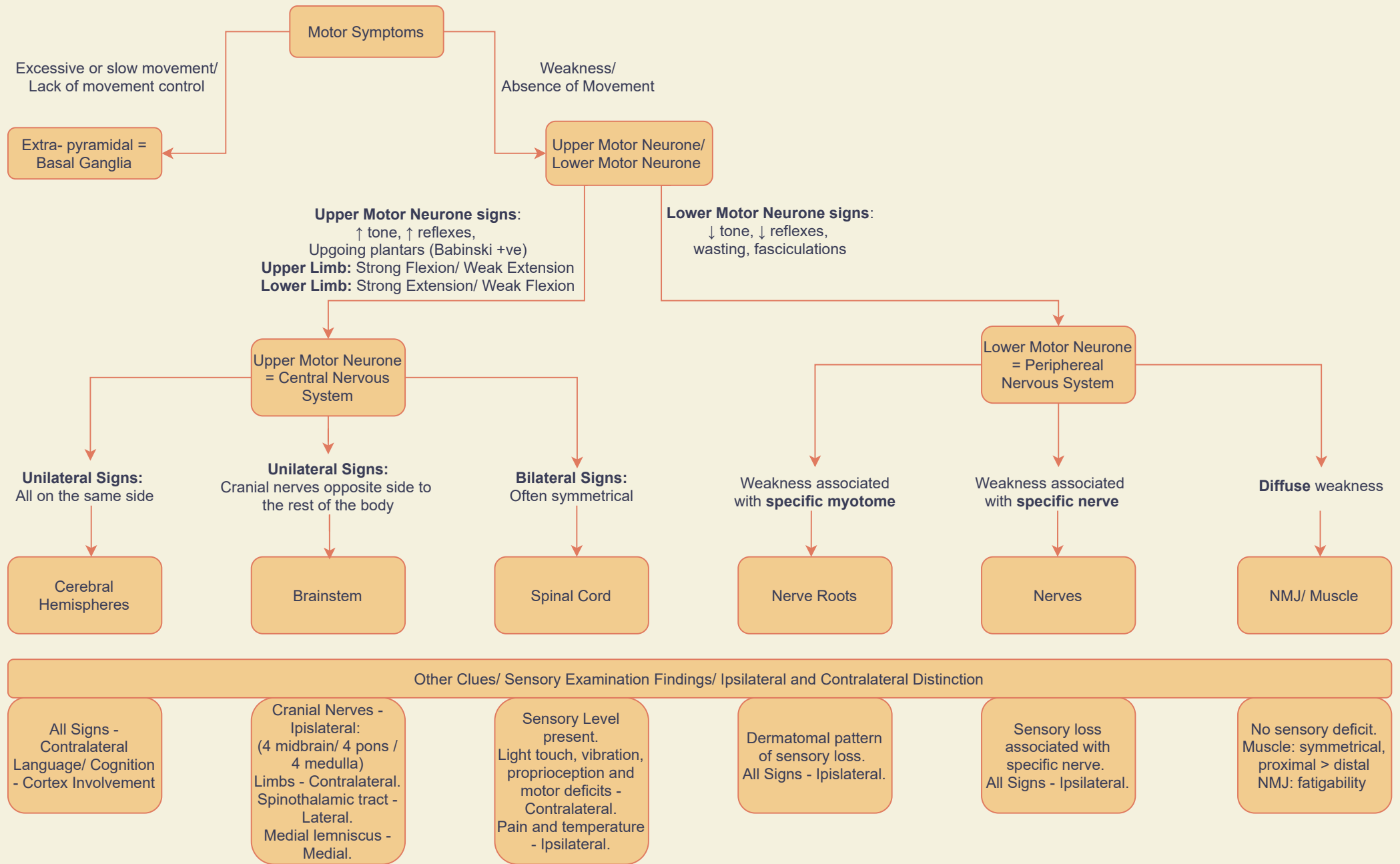


# An approach to... Localisation



## Special situations (Both Upper and Lower Motor Neurone Symptoms):

- 1) Spinal Cord Lesions:** Upper motor neurone below the lesion, lower motor neurone at the level of the lesion. Sensory level.
- 2) Anterior Horn Lesions (Motor Neuron Disease):** a mixture of upper and lower motor neurone signs, sometimes in the same muscle (e.g wasting with brisk reflexes), often asymmetrical;. No sensory deficit.