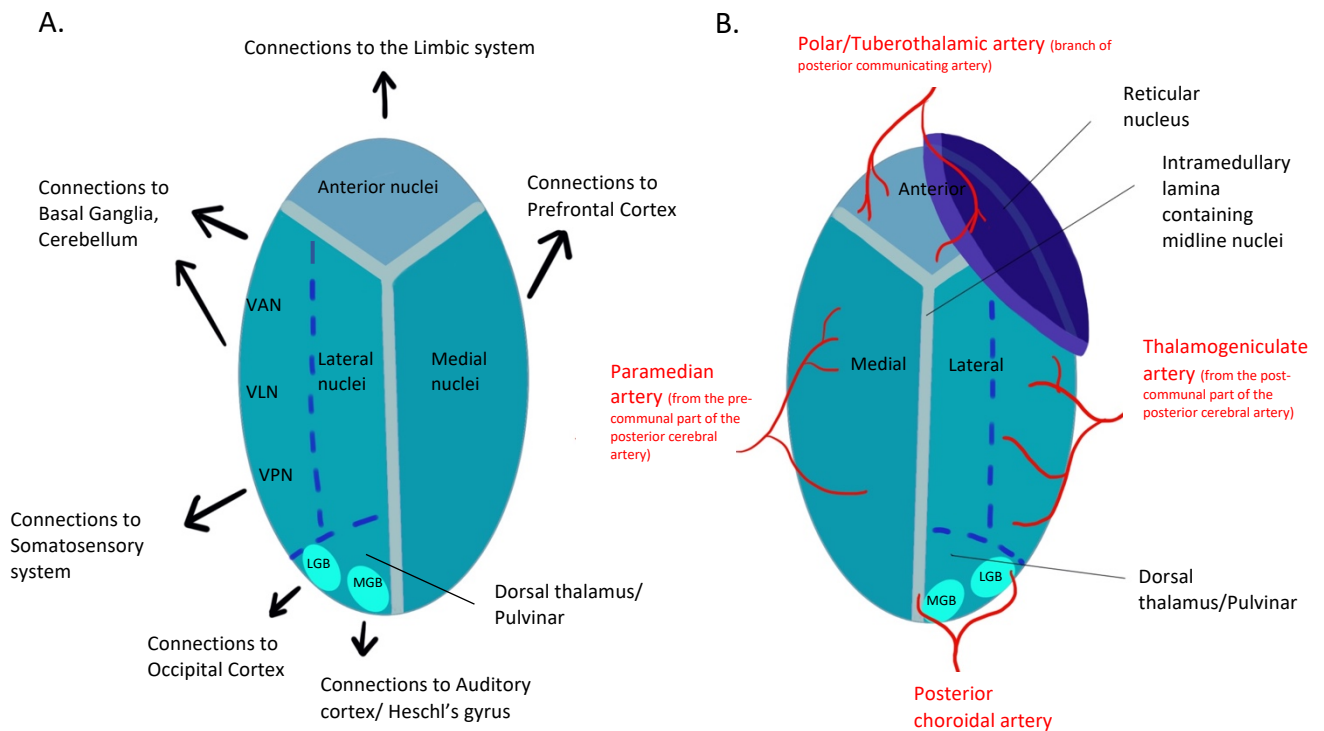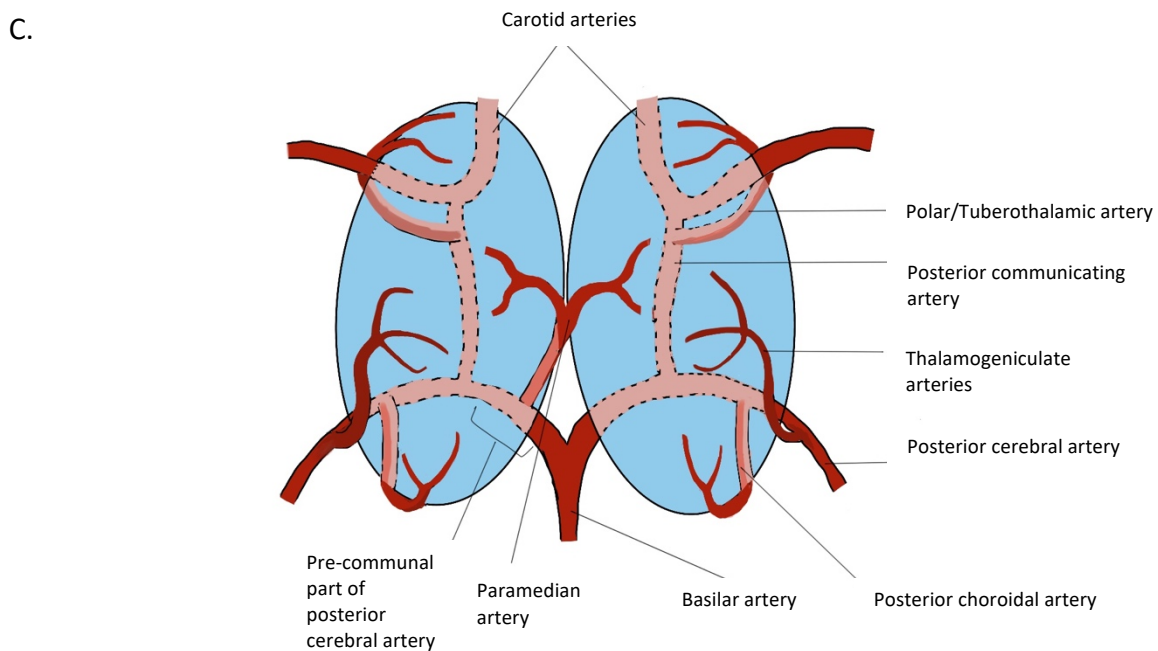


A. Simplified diagram of the thalamus demonstrating gross structure and connections
 B. Simplified diagram demonstrating arterial supply to the thalamus
 VAN= Ventral-anterior nucleus, VLN= Ventral-lateral nucleus, VPN= Ventral-posterior nucleus, LGB= lateral geniculate body, MGB= medial geniculate body



C. Simplified diagram demonstrating arterial supply of the thalamus. This diagram demonstrates the 'Artery of Percheron' anatomical variant. A solitary arterial trunk supplies the paramedian thalami and rostral midbrain bilaterally